

# Schizencephaly Associated with *EMX2* Mutation: A Case Report

Manju O Pai, Divya Aggarwal, Joshi Stephen and Shubha R Phadke

Department of Medical Genetics, Sanjay Gandhi Postgraduate Institute of Medical Sciences, Lucknow, Uttar Pradesh

Email: shubharaophadke@gmail.com

## Abstract

Schizencephaly is a rare human congenital disorder of the brain characterized by abnormal continuity of grey matter tissue extending from the ependymal lining of the cerebral ventricles to the pial surface of the cerebral hemisphere surface. We describe here a 7 year old boy affected with bilateral schizencephaly, born to non-consanguineous parents who presented with intellectual disability, neurologic deficits and seizure disorder. Blood samples collected from the proband and his parents were further processed for sequence analysis. He was found to be heterozygous for a *de novo* point mutation c.473G>A in exon 2 of the homeobox gene *EMX2*. This report together with the earlier reported cases of schizencephaly associated with *EMX2* mutations, support the finding that at least some cases of schizencephaly are caused by deleterious mutations of this homeobox gene. This emphasises the requirement of the *EMX2* protein for correct formation of the human cerebral cortex.

## Introduction

Schizencephaly (SCH) is a rare grey matter malformation of the brain. It is a developmental disorder with a defect in neuronal migration, the causes of which could be an environmental insult or genetic. The role of genetic factors and the only known gene *EMX2* that has been implicated in its etiology in the past, has been a matter of great debate. *LHX2*, a gene with an important cortical patterning role, and *HESX1* and *SOX2* genes that have been associated with septo-optic dysplasia were also checked for association with schizencephaly, but no such association was found (Brunelli et al., 1996; Tietjen et al., 2007; Mellado et al., 2010). The homeodomain transcription factor *EMX2* is

critical for central nervous system and urogenital development.

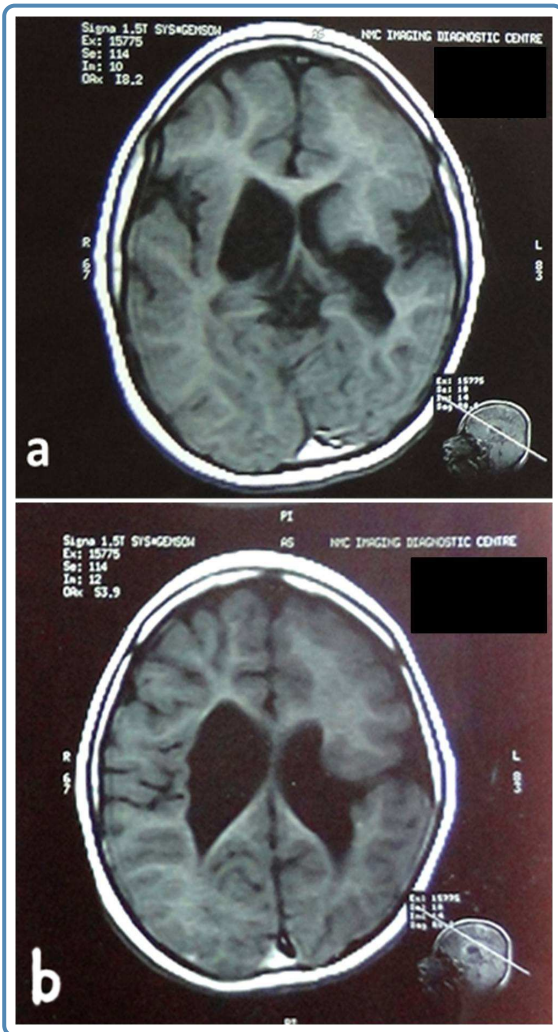
## Case Report

We report a 7 year old boy affected with bilateral schizencephaly with a heterozygous *de novo*, deleterious point mutation in the *EMX2* gene supporting its role in the etiology of schizencephaly. The proband was a 7 year old boy who was born to a non-consanguineous couple at term with no neonatal complications. He had no siblings. He was brought to the outpatient department by the parents with complaints of severe developmental delay noticed since the age of 3-4 months. Neck holding was achieved only after 5 years and even sitting with support had not been attained till the time of presentation. Social smile was present. No meaningful speech was present. The developmental age was 4 months. There was history of seizures since 4 years of age and EEG showed asymmetric background with epileptiform discharges along with left parieto-temporal sharp waves with secondary generalization. On examination at 7 years, height was 114 cm (10<sup>th</sup> centile), weight was 16 kg (3<sup>rd</sup> centile) and head circumference was 43 cms (-4 SD below mean) as per Indian standards.

There was microcornea with corneal diameter being 8 mm (normal-11.5 mm). Teeth were widely spaced with 2 large central incisors. The neurological examination was characterized by severe spasticity along with brisk reflexes in all limbs. The mental impairment was severe with the boy responding only to his mother's voice by gestures with no other communication. A formal development assessment test could not be performed. Rest of the systemic examination was unremarkable.

MRI brain revealed bilateral schizencephaly. On

the left side it was open lip (Type2) and on the right side it was closed lip with grey matter heterotopia (Type1) (Fig 1). Left frontal lobe showed pachygyria and corpus callosum was thin. Ex vacuo ventricular dilatation was seen.

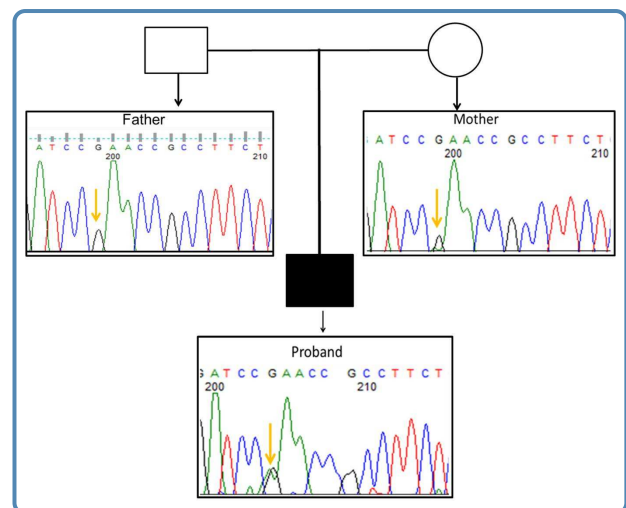


**Figure 1** T1- weighted images of MRI Brain show bilateral schizencephaly. (a) Left frontal lobe showed pachygyria and corpus callosum was thin. Ex vacuo ventricular dilatation was seen. (b) On left side it was open lip (Type 2) and on right side it was closed lip with grey matter heterotopia (Type1).

Blood samples were collected after written consent and approval of the Institute Ethics Committee. Genomic DNA was extracted from the mother, father and proband according to the man-

ufacturer's protocol (Qiagen). Direct sequencing of all the coding exons of the *EMX2* gene was carried out.

The proband was found to be heterozygous for a *de novo* point mutation c.473G>A in exon 2 of the homeobox gene *EMX2*. This mutation leads to the substitution of arginine by glutamine at position 158 (p.Arg158Gln). The mother and father of the proband did not show any change in the sequence pattern. This mutation identified in the proband was predicted to be disease-causing by various mutation-prediction software (SIFT, Polyphen and MutationTaster). The mutation was confirmed to be absent in 50 normal controls. It is a novel variant and has not been reported in the Human Genome Mutation Database (HGMD), Exome Aggregation Consortium (ExAC) and the 1000 genome databases. It is conserved across other species.



**Figure 2** Electropherogram showing homozygosity for the wild type allele in the mother and father (top) and heterozygosity for the *de novo* mutation c.473G>A in the child indicated by the arrow (bottom).

## Discussion

Schizencephaly (SCH) is a congenital brain malformation characterized by full thickness clefts of the cerebral mantle, extending from the pial surface to the lateral ventricles, and lined by heterotopic gray matter. Schizencephaly patients are clinically characterized by motor and mental deficits along with severe epilepsy of varying degree, according to the severity and extent of the brain malformation

species	match	gene	aa alignment
Human			158 HNALARKPKRIRTAFFSPSQLLRLE
mutated	all conserved		158 HNALARKPKRIQTAFSPSQLLRL
Ptroglyodytes	all identical	<a href="#">ENSPTRG00000002981</a>	158 HNALARKPKRIRTAFFSPSQLLRL
Mmulatta	all identical	<a href="#">ENSMMUG00000012415</a>	158 HNALARKPKRIRTAFFSPSQLLRL
Mmusculus	all identical	<a href="#">ENSMUSG00000043969</a>	159 HNALARKPKRIRTAFFSPSQLLRL
Ggallus	all identical	<a href="#">ENSGALG00000009302</a>	153 HNALARKPKRIRTAFFSPSQLLRL
Trubripes	all identical	<a href="#">ENSTRUG00000017831</a>	153 HNALARKPKRIRTAFFSPSQLLRL
Drerio	all identical	<a href="#">ENSDARG00000039701</a>	153 HNALARKPKRIRTAFFSPSQLLRL
Fcatus	all identical	<a href="#">ENSFCAG00000001503</a>	97 HNALARKPKRIRTAFFSPSQLLRL
Dmelanogaster	all identical	<a href="#">FBgn0000576</a>	400 - - - - RPKRIRTAFFSPSQLLKL
Celegans	all identical	<a href="#">C27A12.5</a>	130 RKNKRIRTAFFSASQLIQ
Xtropicalis	all identical	<a href="#">ENSXETG00000022080</a>	153 HNALARKPKRIRTAFFSPSQLLRL

**Figure 3** Comparison with sequences of lower animals shows that the mutation is in the highly conserved site of the gene.

(Brunelli et al., 1996; Tietjen et al., 2007). Two types of schizencephaly have been described depending upon the size of the area involved and fused or open cleft lips. Type 1 contains a fused cleft where the pial ependymal seam forms a furrow in the developing brain and is lined by polymicrogyric grey matter. In type II, there is a large defect, a holohemispheric cleft in the cerebral cortex filled with fluid and lined by polymicrogyric grey matter.

Schizencephaly can arise from a number of environmental factors including maternal trauma, substance abuse, viral infection, in utero vascular accidents in monozygotic twins, and other vascular disruptions (Yakovlev & Wadsworth, 1946; Dominguez et al., 1991; Barkovich et al., 1992; Curry et al., 2005). However, reports of familial schizencephaly and some reports describing similar clinical and radiological features among affected individuals, suggested the possibility of one or more genetic causes (Hosley et al., 1992; Hilburger et al., 1993; Haverkamp et al., 1995; Tietjen et al., 2007)

Initially several reports implicated the *EMX2* (Homolog of *Drosophila* Empty Spiracles 2) transcription factor as a causative gene (OMIM \* 600035) for schizencephaly (Brunelli et al., 1996;

Faiella et al., 1997; Granata et al., 1997; Cecchi, 2002). A total of 18 patients were sequenced for *EMX2* in these studies, and 13 (72%) were found to have various heterozygous mutations including deleterious frameshift, splicing, or deletion mutations. Brunelli et al. (1996) examined 8 patients and found clearly pathogenic *EMX2* gene mutations in 3 patients all of whom had severe type II schizencephaly.

However, later Tietjen et al. (2007) sequenced *EMX2* in a cohort of 84 affected probands, could not identify any pathologic mutations in this cohort and suggested that *EMX2* mutations are an uncommon cause of schizencephaly. More recently Merello et al. (2008) provided results of *EMX2* sequencing in 39 new SCH patients, detecting no pathogenic mutations. They also reinterpreted the results of original articles as showing a significantly lower mutational rate (17%) in *EMX2* than originally reported (72%). Evidence also suggests that some patients with schizencephaly have mutations in genes other than *EMX2* like *SIX3* (OMIM \* 603714), or *SHH* (OMIM \* 600725) genes (Dies et al., 2013).

We have found a *de novo* mutation in the *EMX2* gene in our proband likely pathogenic as it was not found in the normal parents and in the normal

50 controls from the same population. *In silico* data also supports the pathogenic nature of the sequence variation. To the best of our knowledge, the mutation described in this patient has not been reported earlier in literature and databases (Human Genome Mutation Database). Identification of the mutation in the *EMX2* gene in this patient has been of help in providing appropriate genetic counseling to this family. As neither parent has the mutation, it is most likely a *de novo* mutation and therefore the risk of recurrence in the sibs is not increased significantly. However, as reported for many other autosomal dominant disorders, germ-line mosaicism cannot be ruled out and the family needs to be offered early prenatal diagnosis for subsequent pregnancies.

Identification of the *EMX2* gene mutation in this patient supports the role of this gene in the causation of schizencephaly and reinforces the importance of genetic testing in more cases of schizencephaly.

## Acknowledgement

We are thankful to the Indian Council of Medical Research (ICMR), New Delhi (63/8/2010-BMS) for funding this work.

## References

1. Barkovich AJ, et al. Formation, maturation, and disorders of brain neocortex. *AJNR Am J Neuroradiology* 1992; 13: 423-446.
2. Brunelli S, et al.. Germline mutation in the homeobox gene *EMX2* in patients with severe Schizencephaly. *Nature Genet* 1996; 12: 94-96.
3. Cecchi C. *Emx2*: A gene responsible for cortical development, regionalization and area specification. *Gene* 2002; 291: 1-9.
4. Curry CJ, et al. Schizencephaly: heterogeneous etiologies in a population of 4 million California births. *Am J Med Genet* 2005; 137A: 181-189.
5. Dies KA, et al. Schizencephaly: association with young maternal age, alcohol use, and lack of prenatal care. *J Child Neurol* 2013; 28: 198-203.
6. Dominguez R, et al. Brain and ocular abnormalities in infants with in-utero exposure to cocaine and other street drugs. *Am J Dis Child* 1991; 145: 278-279.
7. Faiella A, et al. A number of schizencephaly-patients including 2 brothers are heterozygous for germline mutations in the homeobox gene *EMX2*. *Europ J Hum Genet* 1997; 5: 186-190.
8. Granata T, et al. Familial schizencephaly associated with *EMX2* mutation. *Neurology* 1997; 48: 1403-1406.
9. Haverkamp F, et al. Familial schizencephaly: Further delineation of a rare disorder. *J Med Genet* 1995; 32: 242-244.
10. Hilburger AC, et al. Familial schizencephaly. *Brain Dev* 1993; 15: 234-236.
11. Hosley MA, et al. Schizencephaly: case report of familial incidence. *Pediatr Neurol* 1992; 8: 148-150.
12. Mellado C, et al. Candidate gene sequencing of *LHX2*, *HESX1*, and *SOX2* in a large schizencephaly cohort. *Am J Med Genet A* 2010; 152: 2736-2742.
13. Merello E, et al. No major role for the *EMX2* gene in schizencephaly. *Am J Med Genet* 2008; 146A: 1142-1150.
14. Tietjen I, et al. Comprehensive *EMX2* genotyping of a large schizencephaly case series. *Am J Med Genet* 2007; 143A: 1313-1316.
15. Yakovlev PI, Wadsworth RC. Schizencephaly: a study of the congenital clefts in the cerebral mantle. I. Clefts with fused lips. *J Neuropath Exp Neurol* 1946; 5: 116-130.