

# Novel Bi-allelic Variants in *GJC2* Associated Pelizaeus-Merzbacher-like Disease 1: Clinical Clues and Differential Diagnosis

Veronica Arora, Sapna Sandal, Ishwar Verma

*Institute of Medical Genetics and Genomics, Sir Ganga Ram Hospital, New Delhi*

Correspondence to: Dr Ishwar C Verma Email: icverma@gmail.com

## Abstract

Hypomyelinating Leukodystrophy-2 (HLD2) or Pelizaeus-Merzbacher-like disease 1 (PMLD1) is a slowly progressive leukodystrophy characterized by nystagmus, hypotonia, and developmental delay. It is a close differential diagnosis for Pelizaeus-Merzbacher disease (PMD) and should be suspected in patients with features of PMD but who are negative on testing for duplication of the *PLP1* gene. We describe a case of a 16-month-old boy with a novel homozygous mutation in the *GJC2* gene resulting in hypomyelinating leukodystrophy-2. The clinical clues as well as features of other disorders presenting similarly are discussed.

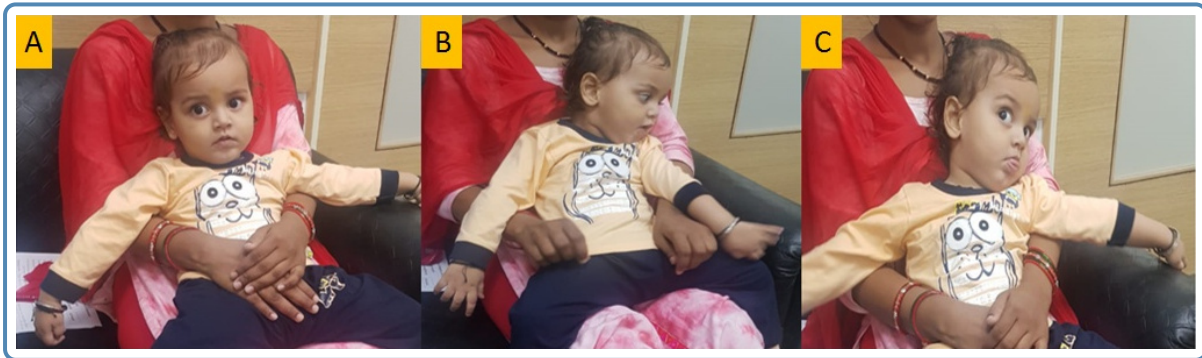## Clinical description

A 16-month-old boy, firstborn of non-consanguineous marriage, was referred to the Genetic Centre for evaluation of delayed developmental milestones. After an uneventful antenatal period, he was born through spontaneous vaginal delivery at 38 weeks of gestation. His birth weight was 3 kg (-0.73 z score) and head circumference was 36 cm (+1.21 z score). He was noticed to have nystagmus at 10 days of age. At 5 months of age, the parents were concerned about his poor developmental milestones. He attained neck holding at 10 months and rolled over from supine to prone position at 11 months. He started recognizing his mother around 5 months of age, babbled at 8 months of age and turned head to sound at 7 months of age. At 16 months of age, he could not sit without support. There was no history of seizures, hearing abnormality, or regression of attained milestones.

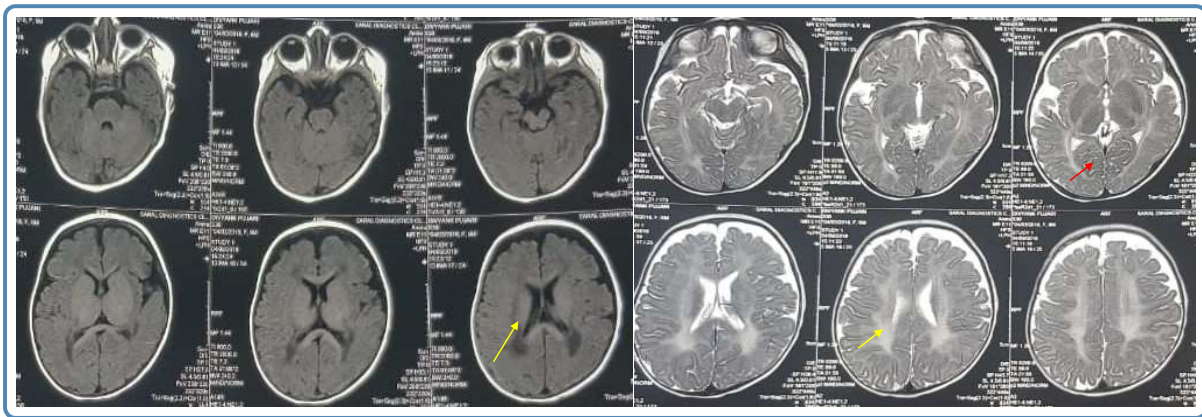
On examination, he was not interactive with

the environment and did not follow objects. Head titubation was present. There was no facial dysmorphism. Anthropometric measurements were as follows: length 82cm (+1.2SD), weight 10.6Kg (+1.1SD) and head circumference 47.7cm (+1.2SD). Central nervous system examination showed bilateral pendular nystagmus, axial hypotonia, dystonic posturing, and choreo-athetoid movements (Figure 1). Deep tendon reflexes were brisk with extensor plantar responses. The rest of the systemic examination was non-contributory. MRI of the brain (axial view) showed diffuse hypo-myelination in the peri-ventricular and sub-cortical area and cerebellar white matter changes (Figure 2).

Given the presence of hypotonia, brisk reflexes, nystagmus and hypomyelination on MRI, a deletion duplication analysis for the *PLP1* gene was done which was negative. Following this, clinical exome sequencing with a focus on exons of genes related to the clinical phenotype was performed. Exome sequencing showed the presence of a homozygous missense variant in the *GJC2* gene [ENST00000366714.2]: c.814T>C; p.(Try272His). This is a novel variant and has not been reported in the 1000 Genome or ExAC database. It is predicted to be damaging by various in-silico prediction tools (MutationTaster, PolyPhen and SIFT). It is conserved across species and is 'likely pathogenic' according to the modified classification as per the American College of Medical Genetics and Genomics (ACMG)/ Association for Molecular Pathology guidelines (PS1+PM2+PP3+PP4). A different missense variation (p.Try272Asp) at this position has been reported in the compound heterozygous state with p.ArgR240Ter in a patient affected with hypomyelinating leukodystrophy (Uhlenberg et al., 2004).



**Figure 1** Proband at age 16 months with neck dystonia, choreo-athetoid movements and dystonic posturing (B and C). Note the dystonic posturing increasing from panel A to C, with severe neck dystonia and tongue thrusting (C).



**Figure 2** MRI Brain: T1 and T2 weighted images showing diffuse involvement of both deep and subcortical white matter of cerebrum (yellow arrows) and cerebellum (red arrows) suggestive of hypomyelination.

## Discussion

Pelizaeus- Merzbacher disease is an X-linked disorder and has been considered the prototype of hypomyelinating leukodystrophies. It is caused by mutation in the proteolipid protein (*PLP1*) gene, on chromosome Xq22. Recently, several hypomyelinating leukodystrophies have been described which mimic the classical PMD and should be considered in the differential diagnosis (Nahhas et al., 2017). In this report, we have described the clinical and neuroimaging features of a 16-month-old boy with global development delay, nystagmus and hypomyelination on MRI, confirmed to have hypomyelinating leukodystrophy type 2 on molecular studies. This entity was first described in 2004 and till date, more than 79 probands have been reported with the disorder

(Uhlenberg et al., 2004; Nahhas et al., 2017).

Hypomyelinating leukodystrophy- 2 (HLD2) is an autosomal recessive disorder caused by homozygous or compound heterozygous pathogenic variants in the Gap Junction Gamma-2 (*GJC2*) gene on chromosome 1q42.13. Gap junction proteins are members of a large family of homologous connexins and comprise 4 transmembrane, 2 extracellular, and 3 cytoplasmic domains. The *GJC2* gene belongs to the family of connexins and encodes for 47 KD gap junction protein (CX47). This gene (OMIM#608803) is exclusively expressed in oligodendrocytes of the brain and plays an essential role in myelination. It has been hypothesized that the reduction of the altered protein in the endoplasmic reticulum, due to mutations in the *GJC2* gene, contribute to the pathogenetic mechanism of CNS-hypomyelination

(Owczarek-Lipska et al., 2019). The clinical features are nystagmus in the neonatal period, developmental delay, dystonia, and ataxia. MRI of the brain shows homogeneous T2 hyperintensities of the cerebral white matter, often in combination with hypointensity on T1-weighted images. Typical prominent T2-hyperintensity of the pons and hyperintensity of the subcortical white matter may be seen in some patients. The basal ganglia and thalami are normal in most patients (Biancheri et al., 2013). Hypomyelination is a group of disorders in which clinical clues are very crucial for diagnosis. The most common ones are the presence of nystagmus (PMD, PMLD1, PMLD2), dystonia and choreoathetosis (Hypomyelination with atrophy of basal ganglia and cerebellum and PMLD1), and hypogonadism (4H syndrome - hypomyelination, hypodontia and hypogonadotropic hypogonadism). Along with the pattern of inheritance and the presence or absence of neuro-regression, the above clues help in narrowing the diagnosis. Gene therapies are increasingly becoming available for neurological disorders. Recently, Li et al. carried out an oligodendrocyte-specific Plp1 gene therapy using micro-RNA using adeno-associated virus leading to widespread suppression of gene function in mouse models (Li et al., 2019). In PMLD1, deletions and duplications are found in about 30% of patients, thus such a therapy may be used. This makes this a potentially treatable disorder and thus should be picked up early.

In conclusion, our report expands the genotypic spectrum of hypomyelinating leukodystrophy-2

and describes a novel gene variant. We also aim to alert pediatricians and pediatric neurologists to keep this disorder in mind, for making a precise diagnosis that would help in genetic counseling, reproductive options and potential therapy in the future.

## References

1. Biancheri R, et al. Expanded spectrum of Pelizaeus-Merzbacher-like disease: literature revision and description of a novel GJC2 mutation in an unusually severe form. *Eur J Hum Genet* 2013; 21: 34–39.
2. Li H, et al. Gene suppressing therapy for Pelizaeus-Merzbacher disease using artificial microRNA. *JCI Insight* 2019; 4(10). pii: 125052. doi: 10.1172/jci.insight.125052. eCollection
3. Nahhas N, et al. Pelizaeus-Merzbacher-Like Disease 1. 2017 Dec 21 [Updated 2019 Jan 17]. In: Adam MP, Ardinger HH, Pagon RA, et al., editors. *GeneReviews®* [Internet]. Seattle (WA): University of Washington, Seattle; 1993-2020. Available from: <https://www.ncbi.nlm.nih.gov/books/NBK470716/>
4. Owczarek-Lipska M, et al. Novel mutations in the GJC2 gene associated with Pelizaeus-Merzbacher-like disease. *Mol Biol Rep* 2019; 46: 4507-4516.
5. Uhlenberg B, et al. Mutations in the Gene Encoding Gap Junction Protein  $\alpha$ 12 (Connexin 46.6) Cause Pelizaeus-Merzbacher-Like Disease. *Am J Hum Genet* 2004; 75: 251–260.